



PATIENT

Cindi Brewer

SPECIES

Canine

BREED

CKCS Mix

SEX

Female Spayed

PRESENTING CLINICAL SIGNS

History: Recheck echo. Grade 3/6 heart murmur. On Vetmedin 2.5mg BID. ALP: 279 T4: 2.1 4Dx neg. -Pertinent previous echo findings (7/2025 SB): CVD B2. LA/AO: 1.75, LV: 3.3, TR: 3.0m/s. Mild AI.

ECHOCARDIOGRAM FINDINGS

2D, m-mode, color flow and doppler imaging is available. Diffuse thickening of mitral valve leaflets (anterior>posterior) with mild prolapse into the left atrial lumen. Severe eccentric mitral regurgitation with moderate left atrial dilation. Normal MR velocity. Mildly increased LV diameter with hyperdynamic myocardial function. The tricuspid valve appears mildly thickened, with mild tricuspid regurgitation. Velocity consistent with early pulmonary hypertension Normal right atrial and ventricular diameter. The pulmonic and aortic valves are normal in morphology and mobility. Normal pulmonic and aortic outflow velocities. Trace aortic and no pulmonic insufficiency. No pericardial or pleural effusion noted. No cardiac tumors observed.

CARDIAC CHART

AGE

9 years

WEIGHT

19.3lbs

INTERPRETED BY

Maggie Machen Lamy,
DVM, DACVIM
(Cardiology)

IMAGING PERFORMED BY

A. Nicastro, DVM

HOSPITAL NAME

Waterway Animal Hospital

REFERRING VET

Dr. Roland

INVOICE

46451

DATE

1/14/26

CANINE CARDIAC PARAMETERS	MR VMAX (m/s)	TR VMAX (m/s)	LA/AO (Boon method)	LA/AO (Heart Base; Swe)	FS (%)	EF (%)	EPSS (cm)
NORMAL PARAMETER	4.5-5.5	<2.7	1.3	<1.6	28-40	40-100	<0.6
PATIENT	6.2	3.0	1.7	1.9	48	80	0.4
CANINE CARDIAC PARAMETERS	HR (BPM)	AV VMAX (m/s)	PV MAX (m/s)	BODY WEIGHT (kg)	LA 2D short axis Base view (cm)	LVIDd Avg; 2D and m-mode short axis (cm)	LVIDs Avg; 2D and m-mode short axis (cm)
NORMAL PARAMETER	50-100	0.7-1.7	0.7-1.6	BELOW	BELOW	BELOW	BELOW
PATIENT	NM	1.0	1.1	8.8	2.7	3.5	1.7
*Normal chamber parameters expressed as a mean value (SD)				3	1.27 (5.3)	2.46 (2.46)	1.36 (5.5)
BODY WEIGHT DEPENDENT PARAMETERS				5	1.40 (4.5)	2.74 (5.2)	1.60 (4.7)
<i>*Note: All measurements based upon multi-modal images and methods. An average value is reported.</i>				10	1.50 (3.8)	3.27 (3.5)	2.06 (3.1)
				15	1.83 (2.0)	3.71 (2.4)	2.43 (2.1)
				20	2.02 (1.9)	4.14 (2.2)	2.80 (2.0)
Adapted from June Boon, Veterinary Echocardiography, 1998				25	2.18 (2.4)	4.48 (2.9)	3.10 (2.5)
Rishniw M and Hollis NE, J Vet Intern Med 2000; 14:429-435				30	2.33 (3.3)	4.83 (3.9)	3.39 (3.4)
Hansson et al, Vet Rad and Ultrasound 2002				35	2.48 (4.3)	5.17 (5.0)	3.69 (4.5)
Bonagura et al. Echocardiography: principles of interpretation, Vet Clin North Am 15:1177, 1995				40	2.62 (5.2)	5.48 (6.1)	3.96 (5.4)
				50	2.88 (7.1)	6.07 (8.3)	4.46 (7.4)

INTERPRETATION OF THE FINDINGS & FURTHER RECOMMENDATIONS

Chronic degenerative valve disease persists with evidence of stability. Severe mitral and mild tricuspid regurgitation are unchanged, without progressive left heart enlargement. Persistently moderate left atrial enlargement indicates there is relatively low risk for imminent complication; however, risk for progression to spontaneous congestive heart failure in the future remains elevated. Pulmonary pressures are stable and the aortic insufficiency remains trace. Routine BP monitoring is advised. No additional issues are identified.

Given a lack of significant progression, it is reasonable to continue Pimobendan lifelong with no obvious indication for additional medications at this time. Continued assessment for progression



PATIENT

Cindi Brewer

SPECIES

Canine

BREED

CKCS Mix

SEX

Female Spayed

AGE

9 years

WEIGHT

19.3lbs

INTERPRETED BY

Maggie Machen Lamy,
DVM, DACVIM
(Cardiology)

IMAGING PERFORMED BY

A. Nicastro, DVM

HOSPITAL NAME

Waterway Animal
Hospital

REFERRING VET

Dr. Roland

INVOICE

46451

DATE

1/14/26

is recommended, with a guarded prognosis (stage B2). That said, stability is certainly a good sign. Patient may be at risk for development of CHF, arrhythmias, and/or sudden death going forward.

Omega fatty acid supplementation and mild salt restriction may also be of some long-term benefit. Monitor for development of a progressive cough, labored breathing, exercise intolerance or collapse episodes.

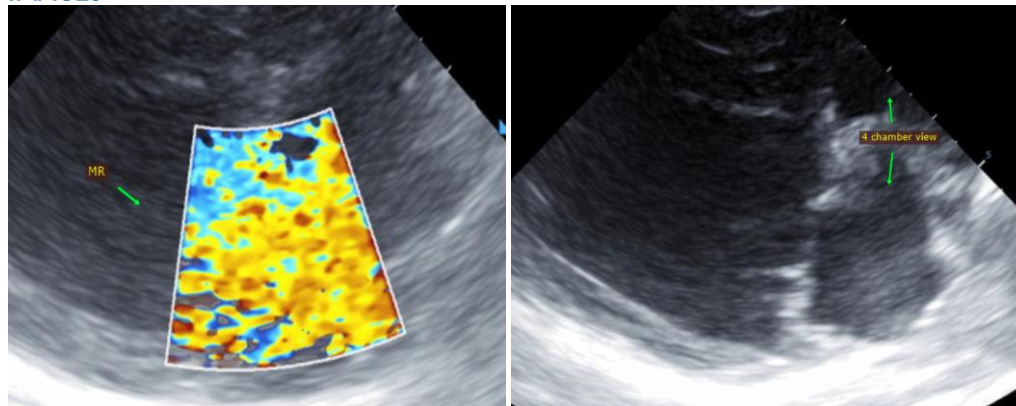
Anesthetic risk remains mildly elevated. Cardiac protective drug choices (opioid/benzodiazepine premedication, Propofol or alfaxalone induction, iso or sevo gas) are recommended. Monitor for arrhythmias, hypotension, and hypoxia both intra and post-operatively and intervene as necessary. Judicious IV fluid rates are recommended to avoid fluid overload. Avoid heart rate stimulating drugs such as atropine unless clinically indicated.

PLAN

Baseline BP recommended every 6 months. Continue Pimobendan 0.25-0.3mg/kg PO q12h.

Recommend monitor for progression with a recheck echocardiogram in 6 months, sooner if any development of clinical signs.

IMAGES



The information and recommendations provided are based on the images presented by the referring veterinarian. No evaluation can be communicated regarding pathology that was not visible in the image/video clips provided.

Thank you for this referral. This report was generated using transcription software, and minor dictation errors may be present. If the clinical or image interpretation does not parallel your findings or if I can be of any further assistance, please contact me.

Maggie Machen Lamy, DVM
Diplomate of the American College of Veterinary Internal Medicine (Cardiology)
info@sonopath.com